
Ultrasound in Second Year Pathology Medical Education

Richard Hoppmann, Wylie E. Michell, John B. Carter, Carol McMahon, Patsy H. Lill, Noel A. Brownlee, and Kevin A. Carnevale

University of South Carolina, Columbia, South Carolina 29208

Reviewed March 24, 2009

Ultrasound machines are becoming smaller and more portable which improves diagnostics at the level of the physical examination alone in certain organ systems. As the technology becomes less expensive and more compact, these machines will be available for use in doctors' offices. Training medical students in this technology from their first year of medical education will better prepare them for the future and presumably improve their diagnostic capabilities. In partnership with General Electric Healthcare, this is currently being performed at the University of South Carolina, one of only two sites chosen nationally for a vertical curriculum training during medical school. In a vertical curriculum setting, ultrasound images and movies coupled with a full presentation of case histories, gross specimen, and microscopic analysis will be incorporated to aid pathology teaching. This vertical curriculum will also encourage medical students to embrace advances in ultrasound technology that will potentially benefit their future practice. It is essential to integrate training in small compact technologies that will improve diagnostic capabilities into all aspects of medical school so that students are fully prepared for future advances. Pathology can play an all encompassing role.

Results and Discussion

Diagnostic ultrasound is an essential part of practice in multiple medical sub-specialties such as cardiovascular medicine, obstetrics/gynecology, emergency medicine, urology, vascular medicine, and surgery. Ultrasound technology was first used in medical practice in the late 1940's and early 1950's and has advanced greatly. With further technological progress, these instruments have become smaller and more portable. Some even predict that as the ultrasound equipment becomes more compact, it will be the new stethoscope of the future.

The General Electric Healthcare LOGIQ e ultrasound system is a portable laptop-sized device that uses a patented CrossXBeam technology to generate sharper border definition and a coded harmonics for higher frequency. It has B steering technology, a 17 inch LCD screen when paired with a portable docking station, and weighs approximately 10 pounds. There are multiple transducers available for use with the device. The transducers are interchangeable and have a wide range of ultrasound frequencies suited for various clinical applications. The array of available transducers allows ultrasound imaging of virtually all organ systems. The LOGIQ e also has advanced features like color doppler flow, power doppler, and pulsed wave doppler that allow for study of cardiovascular system dynamics. In addition, the system is capable of making measurements and calculations in various applications like cardiac, vascular, obstetrical and general ultrasound. Images can be printed on a Sony digital printer or saved to the machine's hard drive or a memory stick. The system has pre-set features for imaging specific organ systems as well as manual

controls to modify scanning parameters such as gain, frequency, depth and focus.

Training medical students for future trends in medicine is essential. Multiple reports have shown that medical students are able to acquire and interpret ultrasound images after a short period of training (Fernandez-Frackelton, 2007; Arger, 2005; and Yoo, 2004). Medical students have also become proficient in such areas as cardiovascular, gynecologic and emergency medical procedures as well as pressure ulcer development (Decara, 2005; Wittich, 2002; Fernandez-Frackelton, 2001; and Quintavalle, 2006). For example, medical students with eighteen hours of hand held ultrasound device training, out performed board-certified cardiologists using standard physical examination by almost 60% in diagnosing lesions producing diastolic murmurs (Kobal, 2005). Their diagnostic accuracy was also superior in recognizing left ventricular dysfunction, enlargement, and hypertrophy.

Presently, cadaver based courses and virtual patient (Tabas, 2005) training allow standardization of ultrasound teaching and learning (Tabas, 2005; Heer, 2004; and Maciellan-Tobert, 1998) and are beneficial to undergraduate and graduate physicians. Therefore, it is necessary to expose future doctors to ultrasound technology, training and images during medical school. Currently, incorporation of ultrasound images and training on compact, laptop devices has been initiated at the University of South Carolina School of Medicine. The medical school is a prime place to begin because of the advanced information technology capabilities and infrastructural support for the development of future ultrasound application. The medical school is also incorporating ultrasound in a vertical curriculum or integrated ultrasound curriculum (iUSC) that involves

training, courses and application from the first year to graduation (Hoppmann, 2006).

Continuous exposure to ultrasound images in a pathology course for medical students has not been previously initiated or emphasized. Our interests include incorporating ultrasound images with gross and microscopic pictures into a second-year pathology course to broaden students' knowledge of cases encountered in different organ systems. For instance, chronic cholecystitis with cholelithiasis (Figure 1) is taught with the ultrasound image to get the clinical diagnostic picture coupled with the pathology. We propose using ultrasound images first in small group teaching whereby students can review the history, physical exam findings, laboratory data, and ultrasound images for individual cases. After studying the ultrasound images, the gross and microscopic changes can be presented as part of the case. This comprehensive overview will not only allow the student to associate the images with the pathological changes but also may help in future understanding of disease processes.

At the University of South Carolina School of Medicine second year students are becoming technologically advanced in their diagnostic capabilities while learning pathology. As our image bank expands, we will incorporate ultrasound images in systemic pathology lectures, particularly involving those of the cardiovascular and male/female genitourinary systems. Single images as well as time lapse ultrasound video will be used to understand flow conditions. This will benefit the understanding of the gross pathology as well as the pathophysiology of disease.

With the ultrasound curriculum added to pathology lectures, students may acquire a more comprehensive overview of disease processes that will better prepare them for the cases they will be encounter routinely during their clinical careers. We expect this will aid the students' ability to understand pathology concepts and further improve their understanding of the pathology seen in the ultrasound images. Early exposure to the ultrasound images, correlated with the gross and pathological changes, may lead to better recall of disease processes. Conversely, improved understanding of tissue densities in different pathological processes may improve understanding of the ultrasound image. Use of ultrasound images in pathology teaching in an integrated curriculum is an innovative approach that will prepare medical students for predictable future trends and enhance their diagnostic capabilities as physicians.

Acknowledgement

General Electric Healthcare generously supports the integrated ultrasound curriculum by providing ultrasound machines and technical support.

Notes and references

1. Fernandez-Frackelton M, Peterson M, Lewis RJ, Perez JE, Coates WC; A bedside ultrasound curriculum for medical students: Prospective evaluation of Skill acquisition. *Teach Learn Med.* 2007 Winter;19(1): 14-9.
2. Arger PH, Schultz SM, Sehgal CM, Cary TW, Aronchick J; Teaching medical students diagnostic sonography. *J Ultrasound Med.* 2005 Oct;24(10): 1365-9.
3. Yoo MC, Villegas L, Jones DB; Basic ultrasound curriculum for medical students: Validation of content and phantom. *J Laparoendosc Adv Surg Tech A.* 2004 Dec;14(6): 374-9.
4. Decara JM, Kirkpatrick JN, Neben MA, Palmer RP, Kasza K, Furlong K, Lang RM; Use of hand-carried ultrasound devices to augment the accuracy of medical student bedside cardiac diagnoses. *J Am Soc Endocardiogr.* 2005 Mar;18(3): 257-63.
5. Wittich CM, Montgomery SC, Neben MA, Palmer BA, Callahan MJ, Seward JB, Pawlina W, Bruce CJ. Teaching cardiovascular anatomy to medical students by using a handheld ultrasound device. *JAMA* 2002 Sept;288(9): 1062-63.
6. Fernandez-Frackelton M, Peterson M, Lewis RJ, Perez JE, Coates WC; Assessing an emergency ultrasound curriculum for medical students. *Acad Emerg Med.* 2001; 8(5) 483.
7. Quintavalle PR, Lyder CH, Mertz PJ, Phillips-Jones C, Dyson M; Use of high-frequency diagnostic ultrasound to investigate the pathogenesis of pressure ulcer development. *Adv Skin Wound Care.* 2006 Nov-Dec;19(9): 498-505.
8. Kobal SL, Trento L, Baharami S, Tolstrup K, Naqvi TZ, Cercek B, Neuman Y, Mirocha J, Kar S, Forrester JS, Siegel RJ; Comparison of effectiveness of hand-carried ultrasound to bedside cardiovascular physical examination. *Am J Cardiol.* 2005 Oct;96(7): 1002-6.
9. Tabas JA, Rosenson J, Price DD, Rohde D, Baird Ch, Dhillon N; A comprehensive, unembalmed cadaver-based course in advanced emergency procedures for medical students. *Acad Emerg Med.* 2005 Aug;12(8): 782-5.
10. Heer IM, Middendorf K, Muller-Egloff S, Dugas M, Strauss A; Ultrasound training: The virtual patient. 2004 Sep;24(4): 440-4.
11. Maciellan-Tobert SG, Buihieu J, Beiohiavek M, Behrenbeck T, Greenleaf JF, Edwards WD, Seward JB; Three-dimensional imaging used for virtual dissection, image banking and physical replication of anatomy and physiology. *Echocardiography.* 1998 Jan;15(1): 89-98.
12. Hoppmann R, Cook T, Hunt P, Fowler S, Paulman L, Wells J, Richeson N, Thomas L, Wilson B, Neuffer F, McCallum J, Smith S; Ultrasound in Medical Education: A Vertical Curriculum at the University of South Carolina School of Medicine. *J South Car Sch Med Assoc.* 2006 Dec, 102: 330-4.

Appendix

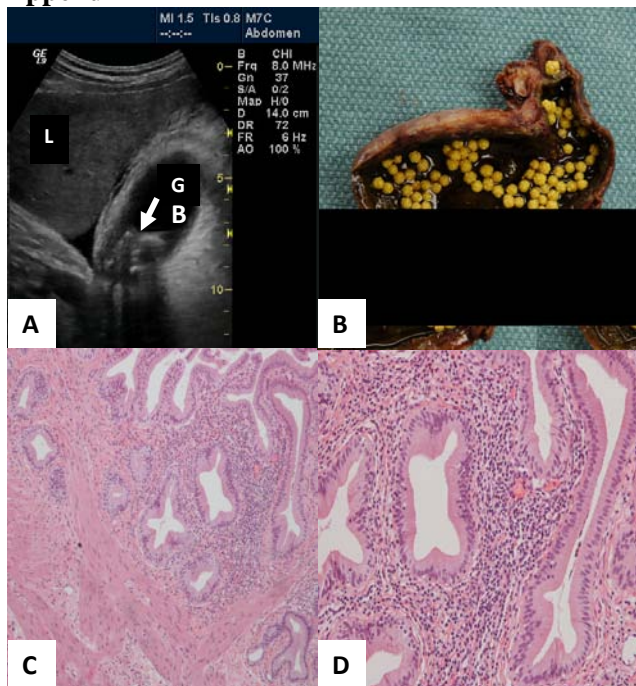


Figure 1. Abdominal ultrasound of the right upper quadrant (A) showing the liver (L) and gallbladder (G). A thickened gall bladder wall with gallstones in the infundibular region of the gallbladder (arrow) results in shadowing on the ultrasound image. Cholecystectomy specimen showing thick wall, erythematous mucosa, and cholesterol stones (B). Low power microscopic section of the gallbladder (C) demonstrates a thickened muscular wall with an inflammatory infiltrate within the lamina propria. Under higher power (D) the inflammatory infiltrate consists primarily of lymphocytes making the diagnosis of chronic cholecystitis with cholelithiasis.